

International Journal of Advanced Multidisciplinary Research (IJAMR)

ISSN: 2393-8870

www.ijarm.com

Research Article

The radix Entomolaris in permanent Mandibular first molar- An Endodontic Challenge

Dr Maneesha Das¹, Dr Priyank Sethi², Dr Kavitha³, Dr Abhishek Singh Nayyar^{4*}

¹Senior Lecturer, Department of Conservative and Endodontics, Saraswati-Dhanwantari Dental College and Hospital, Post-Graduate and Research Institute, Parbhani, Maharashtra, India

²Senior Lecturer, Department of Conservative and Endodontics, Saraswati-Dhanwantari Dental College and Hospital, Post-Graduate and Research Institute, Parbhani, Maharashtra, India

³Senior Lecturer, Department of Conservative and Endodontics, Saveetha Dental College and Hospital, Chennai, Tamil Nadu, India

⁴Reader, Department of Oral Medicine and Radiology, Saraswati-Dhanwantari Dental College and Hospital, Post-Graduate and Research Institute, Parbhani, Maharashtra, India

*Corresponding Author

Keywords

Radix Entomolaris, three-rooted mandibular first molar, anatomic variations, bilateral occurrence, distolingual root.

Abstract

A thorough and complete understanding of the root canal anatomy and its variations is of utmost significance for the overall success of root canal therapy. Permanent mandibular first molars generally have two roots mesial and distal and three root canals. But they can have an additional root located lingually known as Radix Entomolaris or buccally called as Radix Paramolaris. Its prevalence differs significantly with different racial groups with a very low percentage of occurrences seen in Indian population. This case report highlights the clinical and radiographic identification followed by the endodontic management of radix entomolaris in mandibular molars.

Introduction

The success of any endodontic treatment depends upon the thorough biomechanical preparation of the root canal followed by three dimensional obturation providing a hermetic seal. Hence, knowledge about the anatomy of the pulp chamber and the root canal system along with its potential variations are an indispensable part of endodontics.^{1,2} Majority of the permanent mandibular first molars have two roots namely mesial and distal with three root canals. The mesial root generally has two root canals having two distinct apical foramen which might merge at the root tip to form one foramina. The distal root generally has a kidney shaped root canal with narrow and round orifice if another distal canal is present. The additional root may be present distolingually known as Radix Entomolaris as first described by Carabelli. Identification and external morphology of these root complexes containing buccal or lingual supernumerary root has been first described by Carlsen and Alexandersen. Apart from mandibular first molars, sometimes it may be found

rarely in mandibular third molars but has not been reported in second molars.^{3,4} Knowledge about the complex anatomy of the root canal including canal numbers and its divisions (Weine et al 1969, Allen et al 1989) along with the variations in tooth and root canal anatomy and racial groups significantly contributes to the predictability of the root canal treatment (Walker 1988).^{5,6}

Endodontic literature reveals incidence of radix entomolaris most commonly among Mongloids and Eskimos (43.7%), followed by Taiwanese (Chinese) (21.1-33.33%), less than 5% in Eurasian and Asians, 4.2% in Caucasians, 3% in Africans and least among Indians (0.2%). Curzon⁷ (1974) suggested occurrence of radix entomolaris had high degree of genetic penetrance, mostly in Eskimos and Eskimo/Caucasian mixed populations. Donnison (1970) suggested mostly Burmese populations as having mongloid traits. According to Ramesh Bharti et al it was found that females had higher prevalence of

unilateral Radix Entomolaris (mostly right molar), whereas males recorded equal prevalence of unilateral and bilateral Radix Entomolaris.⁸ This case report discussed below describes the diagnosis and management of Radix Entomolaris in mandibular first molars during the endodontic therapy.

Case 1

A 28 year old female patient reported with a chief complaint of pain in the lower left back region of the mouth since 10 days. The pain was continuous in nature and it was aggravated on intake of hot and cold foods and also during mastication. No significant medical history was recorded. Clinical examination of 36 revealed deep occlusal carious lesion and it was tender upon vertical percussion. Thermal and electric pulp vitality tests showed intense and prolonged response. Intraoral periapical radiograph revealed deep caries with pulpal involvement associated with periapical changes like widening of periodontal ligament space around the apical area of the mesial root. Presence of an additional periodontal ligament space crossing over the distal root gave the impression of double periodontal ligament space on the distal aspect leading to the diagnosis of an additional extra root. Hence the patient was diagnosed with acute apical periodontitis after thorough clinical and radiographic examination and was suggested for endodontic therapy.

Root canal treatment was initiated after anaesthetizing the tooth under rubber dam isolation. Access opening was done using the Endo-access bur and one distal and two mesial canals were located using DG-16 endodontic explorer. A dark line was observed between the distal canal orifice and distolingual corner of pulp chamber. The overlying dentin in this area was removed using a diamond bur with non cutting tip (Diamendo, Dentsply Maillefer). The fourth distolingual canal was located far from the distal root canal orifice. Pulpal tissue remnants was removed and canals initially were negotiated using no 10 K-file (Dentsply Maillefer,Switzerland). The orifices of the root canals were enlarged using Gates Glidden drills (Dentsply Maillefer, Switzerland). The working lengths were radiographically determined using a no 15 K-file and an apex locator (Root ZX, Morita, Tokyo, Japan) and radiograph was taken with a mesial angulation to verify the working length and confirm the extra distolingual root. Canals were cleaned and shaped using 3% sodium hypochlorite solution, 2% chlorhexidine as irrigants along with EDTA and Protaper rotary nickel titanium files (Dentsply Maillefer,Switzerland). Calcium hydroxide intracanal medicament was given and the access opening was sealed with zinc oxide eugenol cement (DPI India) and patient was recalled after one week for review and further treatment. Intracanal medicament of calcium hydroxide dressing was changed and repeated in case patient was found symptomatic. In the following appointments when the patient was completely asymptomatic, it was decided to obturate the tooth. Master cones (Dentsply Maillefer,Brazil) were selected

and radiograph was taken to check for the fit of the cones. Canals were dried using paper points and obturation was done using AH Plus sealer (Dentsply De Trey, Konstanz, Germany) and lateral compaction technique of obturation. After obturation, the access cavity was sealed with zinc oxide eugenol cement (DPI India). Patient was scheduled for follow up visits. The healing was found to be uneventful. (Figure-1(a), (b),(c))

Case 2

A 35 year old male patient reported with a chief complaint of acute pain in lower left back region of the mouth. The pain was aggravated on intake of cold foods. Radiographically, no signs of widening of the periodontal ligament space were seen. Hence patient was diagnosed with chronic irreversible pulpitis. Radiographically, one mesial root and two distal roots were observed. The patient was suggested for endodontic therapy. Access opening was done under local anaesthesia and rubber dam isolation using Endo Access bur. Careful exploration of the pulp chamber floor of the access cavity using DG-16 endodontic explorer revealed two distal canal orifices and two mesial canal orifices. Orifices of the canals were enlarged using Gates Glidden drills and were initially negotiated using no 10 K-file (Dentsply Maillefer,Switzerland). The root canal working lengths were radiographically determined using a no 15 K-file and an apex locator (Root ZX, Morita, Tokyo, Japan). Radiograph was taken using SLOB technique to verify the working length and confirm the extra distolingual root. Canals were cleaned and shaped using 3% sodium hypochlorite solution, 2% chlorhexidine as irrigants along with EDTA and Protaper rotary nickel titanium files (Dentsply Maillefer,Switzerland). Calcium hydroxide intracanal medicament was given and the access opening was sealed with zinc oxide eugenol cement (DPI India) and patient was recalled after 5 days for review and further treatment. Next appointment when the patient was completely asymptomatic, master cones (Dentsply Maillefer,Brazil) were selected and radiograph was taken to check for the fit of the cones. Canals were dried using paper points and obturation was done using AH Plus sealer (Dentsply De Trey, Konstanz, Germany) and lateral compaction technique of obturation. After obturation, the access cavity was sealed with zinc oxide eugenol cement (DPI India). Patient was then scheduled for follow up visits. The healing was found to be uneventful. (Figure-2(a), (b), (c))

Discussion

The prevalence of Radix Entomolaris in mandibular first molars has been well documented in the literature. It is associated with various ethnical groups with the highest frequency (5-30%) observed in populations with Mongloid traits (such as Chinese, Eskimos and American Indians). In Caucasians, it was not so common with maximum frequency of 3.4-4.2%. In African populations, it is around 3% with least

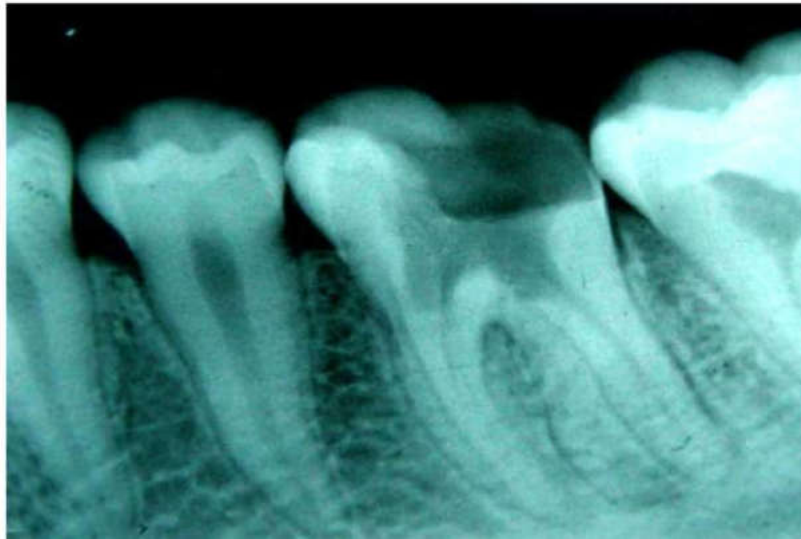


Fig 1(a) Pre-operative radiograph

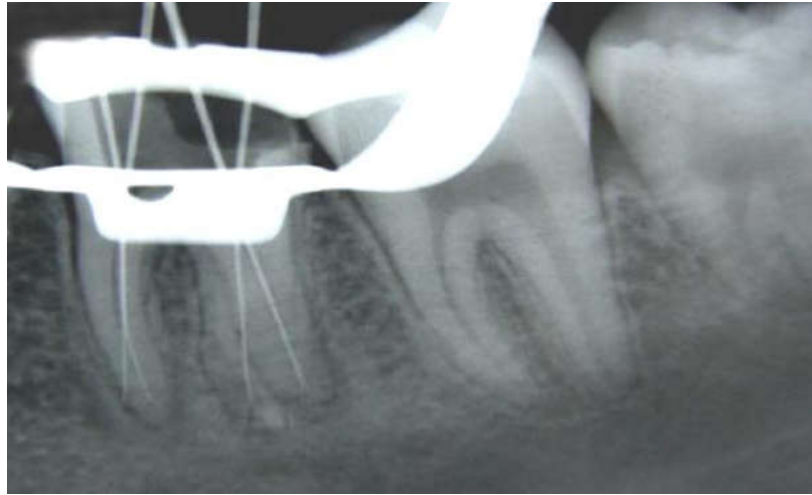


Fig 1(b) Master cone selection radiograph

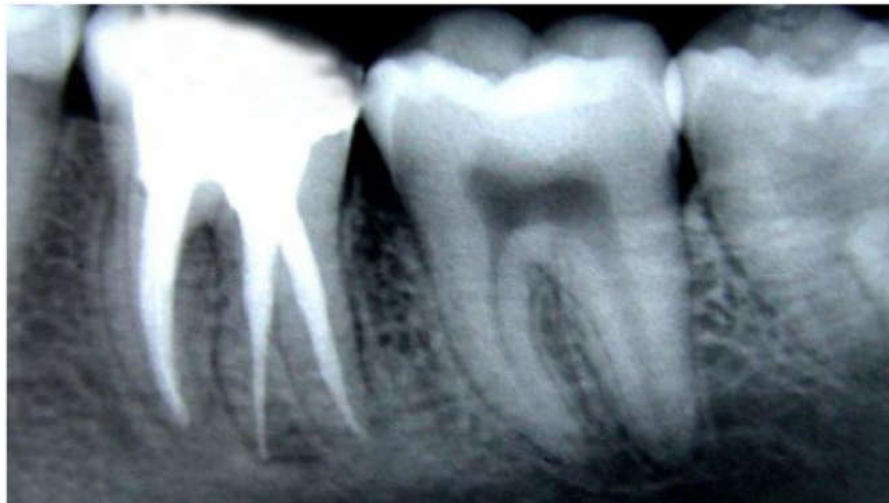

Fig 1(c) Post-obturation radiograph

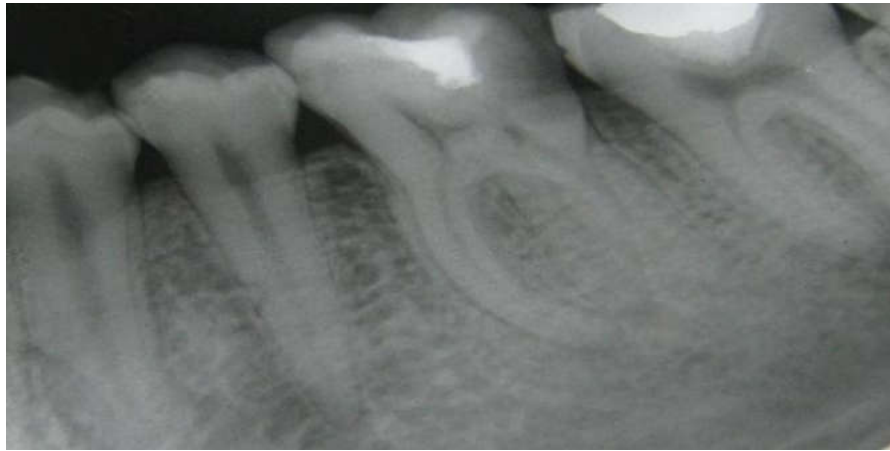

Fig 2(a) Pre-operative radiograph

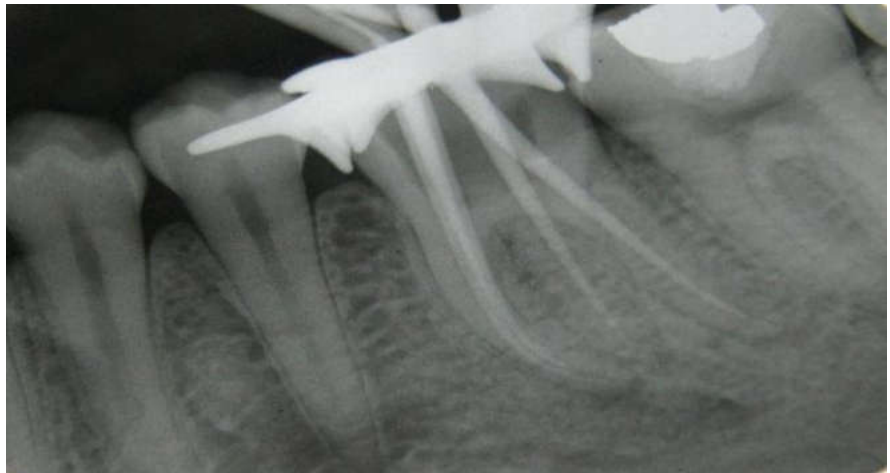


Fig 2(b) Master cone selection radiograph

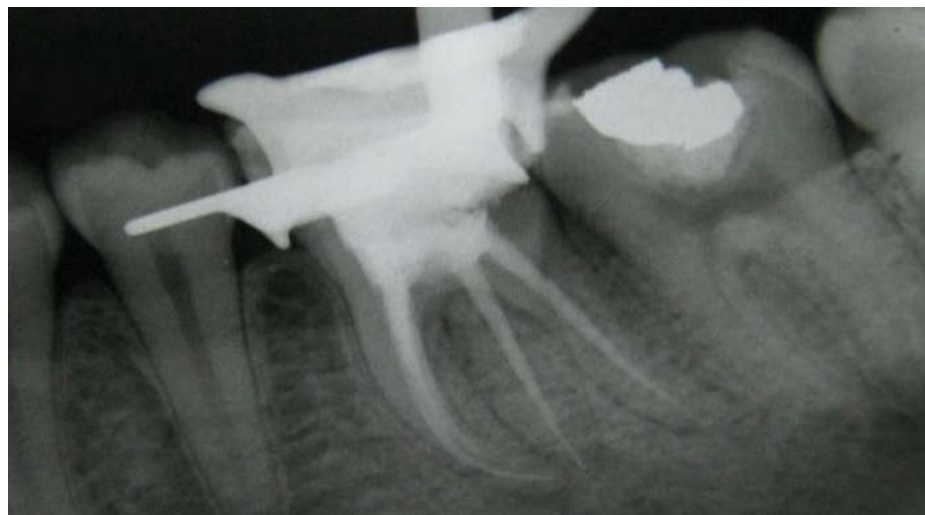


Fig 2(c) Post-obturation radiograph

occurrence among Indians (0.2%).⁹ The etiology behind Radix Entomolaris might be due to external factors during odontogenesis or penetrance of an atavistic gene or polygenetic system. Atavism is the condition where there is reappearance of a trait after several generations of absence. It can also be found in second and third mandibular molars with least occurrence in second molar. Bilateral occurrence of Radix Entomolaris was also reported in 50-67% cases.¹⁰ Radix Entomolaris is an additional extra root located distolingually and its dimensions can vary from a very short conical extension upto a mature root with normal length and root canal system. Carlsen and Alexandersen classified Radix Entomolaris into four types based on the location of the cervical part of Radix Entomolaris.

Type A and B -> Distally located cervical part of Radix Entomolaris with two normal and one distal root components.

Type C -> Mesially located cervical part of Radix Entomolaris.

Type AC -> Central location of Radix Entomolaris between the distal and mesial root components.

An additional classification was given by De Moor et al based on the curvature of separate Radix Entomolaris in bucco-lingual orientation.

Type I -> Straight root/ Root canal.

Type II -> Initially curved and later continued as a straight canal.

Type III -> Initially curved in the coronal third of the root canal and then a second curve beginning in the middle and continuing upto the apical third of the root canal.¹¹

An increase in the number of cusps doesn't always necessarily be related to increased number of roots; but an additional root is always associated with increased number of cusps like an extra cusp (Tuberculum paramolare). Variations in the root canal anatomy can be easily detected using mesial or distal angled radiographs upto 20 degrees using Buccal Object rule as first described by Clark. According to this rule, if mesial angulation is given, lingual canal appears mesial and buccal canal as distal. A thorough inspection of the preoperative radiograph will reveal Radix Entomolaris by interpretation of various characteristics such as unclear view of the distal root contour or the root canal.¹²

Clinical inspection of the tooth crown and analysis of the cervical morphology of the roots using a periodontal probe would also help locating the Radix Entomolaris. Magnification aids like loupes, intra-oral camera, oroscope and dental operating microscope also helps in better visualisation of the pulp chamber floor. Other methods of locating additional canals include champagne bubble test, usage of dyes such as methylene blue, fluorescein sodium

ophthalmic dyes, ultrasonics, micro CT and visualization endogram using Ruddle's solution. It is generally seen as a dark developmental line on the pulp chamber floor from the distal orifice. The distal and lingual pulp chamber wall can be explored with an angled probe to reveal any overlying dentin covering the Radix Entomolaris orifice. Such calcification should be necessarily removed to obtain straight line access upto the apical foramina. The access cavity is then accordingly modified into a trapezoidal form. Calculating the mean inter-orifice distance between the extra distolingual canal and the remaining canals as described by Tu et al can also serve as a guide to locate the Radix Entomolaris.^{13,14}

In cases of severely curved root canals, (Type III RE), iatrogenic errors like straightening of the root canal, ledge formation, loss of working length or root canal transportation may occur in the apical third of the root canal during the biomechanical preparation. Hence, using flexible nickel-titanium rotary files in such cases allows for a more centered root canal preparation with restricted enlargement of the coronal third of the root canal and orifice relocation. But chances of file breakage are more commonly seen in severely curved canals. Hence root canal should be initially explored using a no 10 size k file followed by radiographic determination of working length and then negotiation of the curved root canal system to establish a very systematic glide pathway upto the apical foramina.¹⁵

Conclusion

The prognosis of the root canal treatment depends upon the careful observation and interpretation of radiographs to avoid missing any extra canals. Hence knowledge about the unusual root canal morphologies in terms of root inclination and root canal curvatures among various ethnical groups is important. Due to the high frequency of a fourth canal in mandibular first molars, it is very important to anticipate and identify this canal during endodontic therapy. Possibility of any extra root should be considered and located for carefully. Clear, undistorted preoperative periapical radiographs exposed at two different horizontal angulations are necessary to identify these additional roots. Strategy of establishing a straight line access of the cavity upto the apical foramen need to be emphasized since most of the radix entomolaris cases have curved roots. Such careful approaches would definitely lead to successful treatment outcomes and avoid or overcome any of the procedural errors during endodontic therapy.

References

- 1)Prabhu NT, Munshi AK. Additional distal root in permanent mandibular first molars: report of a case. Quintessence International 1995; 26(8): 567-569.

- 2) Barker BC, Parson FC, Mills PR, William GL. Anatomy of the root canals III. Permanent mandibular molars. *Aust Dent J* 1974;19:403-413.
- 3) Carlsen O, Alexandersen V. Radix entomolaris : identification and morphology. *Scan J Dent Res* 1990;98:363-373.
- 4) Calberson FL, De Moor RJ, Deroose CA. The Radix entomolaris and paramolaris. *J Endod* 2007;33:58-63.
- 5) K Gulabivala, T.H.Aung, A. Alavi, Y.L.Ng. Root and canal morphology of Burmese mandibular molars. *International Endodontic Journal* 2001;34:359-370
- 6) Tu MG, Tsai CC, Jou MJ. Prevalence of three-rooted mandibular first molars among Taiwanese individuals. *J Endod* 2007;33:1163-1166.
- 7) Tratman EK. Three-rooted lower molars in man and their racial distribution. *Br Dent J* 1938;64:264-274
- 8) Ramesh Bharti, Deeksha Arya, Saumyendra V S, Kulwinder KW. Prevalence of Radix Entomolaris in an Indian Population. *Indian J Stomatol* 2011;2(3):165-167.
- 9) Curzon ME. Miscegenation and the prevalence of three-rooted mandibular first molars in the Baffin Eskimo. *Community Dent Oral Epidemiol* 1974;2:130-131.
- 10) Ferraz JA, Pecora JD. Three-rooted mandibular molars in patients of Mongolian, Caucasian and Negro origin. *Braz Dent J* 1993;3:113-117.
- 11) De Moor RJ, Deroose CA, Calberson FL. The radix entomolaris in mandibular first molars: an endodontic challenge. *Int Endod J* 2004;37:789-99.
- 12) Col Albert C, Goerig, Elmer J. Neaverth. A Simplified look at the Buccal Object Rule in Endodontics. *J Endod* 1987;13:570-572.
- 13) Tu MG, Huang HL, Hsue SS, Hsu JT, Chen SY, Jou MJ. Detection of permanent three-rooted mandibular first molar by cone-beam computed tomography imaging in Taiwanese individuals. *J Endod* 2009;35:503-7.
- 14) Christie WH, Thompson GK. The importance of endodontic access in locating maxillary and mandibular molar canals. *J Canad Dent Asso* 1994;60:527-32.
- 15) Slaus G, Bottenberg P. A survey of endodontic practice among Flemish dentists. *International Endodontic Journal* 2002;35:759-767.